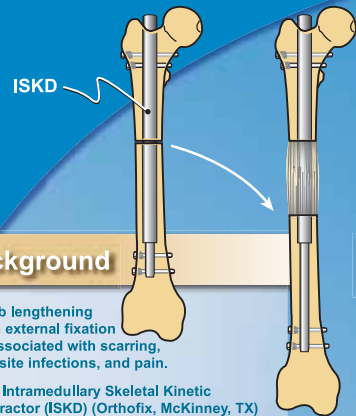


# Intramedullary Skeletal Kinetic Distractor (ISKD) for Posttraumatic Limb Length Discrepancy

John E. Herzenberg, MD, Gaurav Jindal, MD, Mohan V. Belthur, MD, Dror Paley, MD, and Stacy C. Specht, MPA

Research conducted at the International Center for Limb Lengthening, Rubin Institute for Advanced Orthopedics, Sinai Hospital of Baltimore, Baltimore, Maryland

All products discussed in this poster have received Food and Drug Administration approval for the uses described. Disclosures: Research support from Orthofix, Inc. (JEH, GJ, MVB, DP, SCS) and consultant for Orthofix, Inc. (DP).



## Background

- Limb lengthening with external fixation is associated with scarring, pin-site infections, and pain.
- The Intramedullary Skeletal Kinetic Distractor (ISKD) (Orthofix, McKinney, TX) is an internal, mechanically activated lengthening device.
- The ISKD is designed to increase patient comfort while reducing complications associated with limb lengthening.

## Materials

- Prospective study (2001–2006)
- 28 patients (28 limbs) with posttraumatic limb length discrepancy (LLD)
- Femoral lengthening: 23 limbs
- Tibial lengthening: 5 limbs
- Average age: 35 years (range, 13–55 years)
- Average LLD: 3 cm (range, 2–6 cm)
- Preoperative and follow-up Enneking scores (maximum 30 points) were obtained to assess:
  - Pain
  - Function
  - Walking
  - Emotional acceptance
  - Assistive device use
  - Gait

## Results

- 26 (93%) of 28 limbs achieved desired amount of lengthening.
  - 2 of 28 limbs failed to completely distract, both which healed after exchange nailing.
    - One case of stiff hypertrophic nonunion resulted in a final LLD of 11 mm
    - One case of varus malunion resulted in a LLD of 20 mm
- Enneking scores (available in 17 subjects) significantly improved by 7 points (P value = 0.001)
- Unplanned procedures were performed in 25% of patients

RESULTS	
Preoperative LLD:	35 mm (17–58 mm)
Length obtained:	32 mm (6–58 mm)
Distraction rate:	1.2 mm/day (0.5–3.5 mm/day)
Bone healing index*:	0.9 month/cm
Follow-up:	18 months (6–40 months)

LLD, limb length discrepancy.  
\*Time to full weight bearing; excludes nonunion (2)

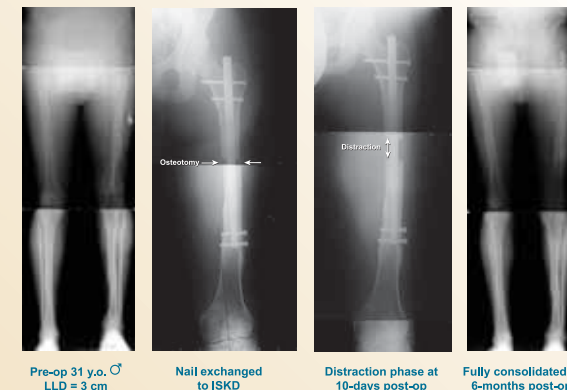
COMPLICATIONS	TREATMENTS
Stuck nail (n=2)	Manipulation under anesthesia (n=2)
Premature consolidation (n=1)	Re-osteotomy (n=1)
Partial union (n=2)*	ICBG (n=1) Exchange rod and ICBG (n=1)
Nonunion (n=2)	Exchange nailing (n=2)

\*Partial union = healed on one cortex only  
ICBG, iliac crest bone graft.

## Conclusions

- ISKD lengthening is safe and effective for posttraumatic LLD.
- A staged procedure is recommended to treat nonunion or malunion. Once the bone is healed and/or straightened, lengthening can be considered (exchange nailing with ISKD).
- Complication rates are acceptable.

## Case Example



Pre-op 31 y.o. ♂  
LLD = 3 cm

Nail exchanged  
to ISKD

Distraction phase at  
10-days post-op

Fully consolidated at  
6-months post-op

## References

- Hankemeier S, Gössling T, Pape HC, et al. Limb lengthening with the Intramedullary Skeletal Kinetic Distractor (ISKD). *Oper Orthop Traumatol* 17:79–101, 2005.
- Cole JD, Justin D, Kasparis T, et al. The intramedullary skeletal kinetic distractor (ISKD): first clinical results of a new intramedullary nail for lengthening of the femur and tibia. *Injury* 32 Suppl 4:129–139, 2001.
- Thonse R, Herzenberg JE, Standard SC, et al. Limb lengthening with a fully implantable, telescopic, intramedullary nail. *Op Tech Ortho* 15:335–362, 2008.